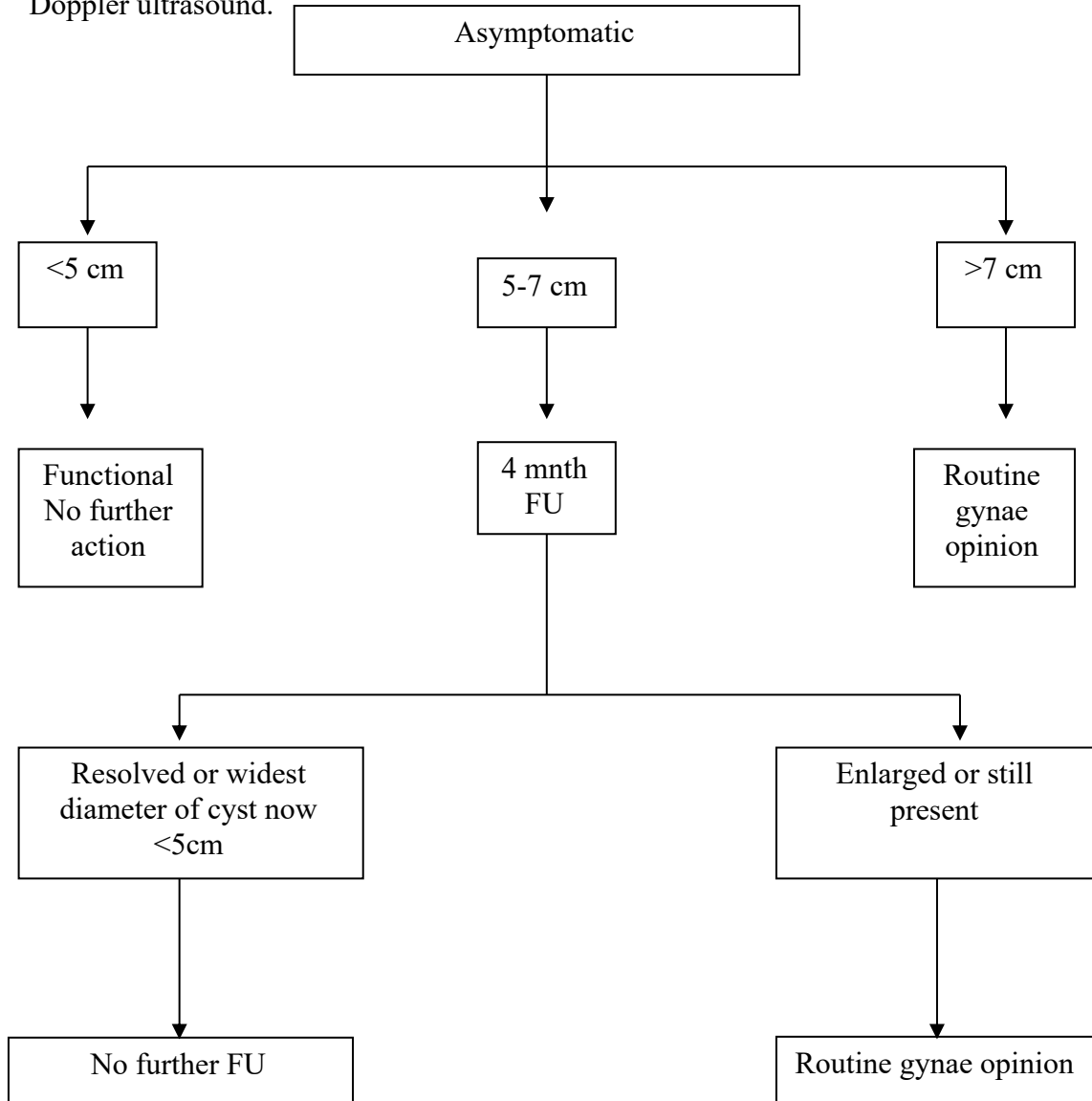


Premenopausal Ovarian Cysts

A simple cyst is a round or oval anechoic space with smooth thin walls, posterior acoustic enhancement, no solid component or septation and no internal flow at colour Doppler ultrasound.



- The following cysts should also be treated as simple and the same size thresholds used: para ovarian cysts where the ovary can be seen separately, cysts containing daughter cysts and cysts with one thin septation (<3mm) or small calcification in wall.
- Always refer to previous imaging if possible CT/MRI/US.
- Make explicit in report who is to arrange follow up.
- Symptomatic cysts may need referral.
- If there is any increasing complexity or pointers to malignancy at US, 2WW gynae referral is recommended.