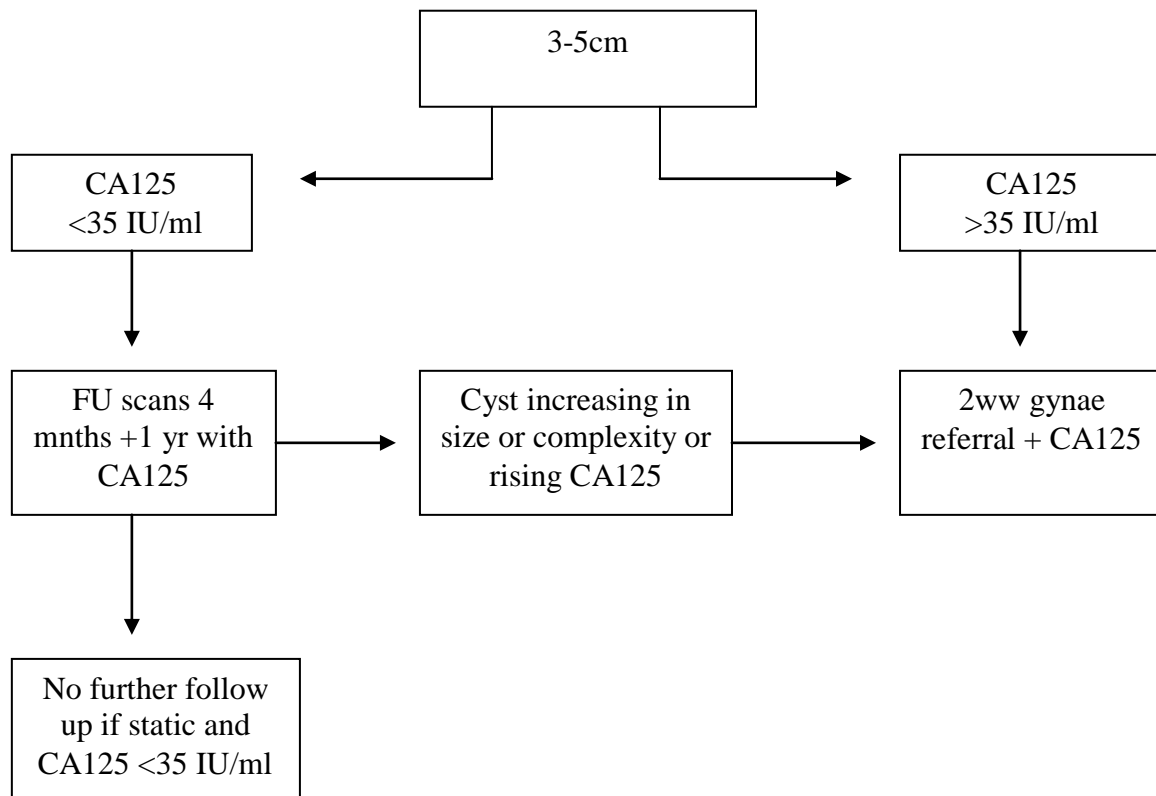


Post Menopausal Simple Ovarian Cysts

These are for simple cysts or cysts with one thin septation (<3mm) these are a round or oval anechoic space with smooth thin walls, posterior acoustic enhancement, no solid component or septation and no internal flow at colour doppler ultrasound.



- Simple cysts <3cm need no follow up
- One thin septation (<3mm) or small calcification in wall is almost always benign. Treat as simple and follow up according to size of cyst.
- Cysts > 5cm recommend CA125 and refer as appropriate. (local guidance)
- Complex ovarian cysts of any size recommend urgent referral to gynae 2ww clinic with CA125. Use doppler to assess solid elements/ papillary projections
- Symptomatic cysts of any size may need gynae referral
- Always review previous imaging US/CT/MRI if available – if unchanged over one year then no need to follow up
- Ask GP to check CA125 and arrange FU as above
- In cases suspicious for metastatic malignancy discuss with radiologist with regard to CT