

Ultrasound Detection of Hamstrings Tears: A Less Usual Cause for Hip Pain

Dartford and Gravesham NHS Trust

M Ho¹, S Menon¹, L Meacock², S Morgan¹, G.Constantinescu¹

King's College Hospital NHS Foundation Trust

¹ Darent Valley Hospital NHS Trust
² Kings College Hospital NHS Trust

Introduction:

Hip pain is a common presentation in general practice and orthopaedic clinics. Causes of hip pain are sub-divided into intra-articular and extra-articular in origin. In our study, we outline the usefulness of high resolution ultrasound in the diagnosis of full and partial hamstring tears, one of less commoner causes of hip pain.

Patients with hamstring injuries usually present as follows:

- Sudden onset of hip / buttock pain
- Felt a "pop" in hip / buttock
- Pain worsening on movement of affected limb
- Pain when sitting

High resolution ultrasound is an invaluable diagnostic modality for acute hamstring injuries.

Aims:

Demonstrate the value of high resolution ultrasound in detecting full and partial thickness tears of the hamstrings attachment on the ischial tuberosities.

Demonstrate the value of high resolution ultrasound as an adjunct to guide intervention.

Materials & Methods:

191 (n=191) patients presenting with hip pain were evaluated, within a 6-month period, using ultrasound, by 4 dedicated musculoskeletal radiologists.

- **Females** = 112
- **Males** = 79
- **Age range:** 49 and 91, with a preponderance of patients in their 6th and 7th decades

The referring diagnoses were, in most cases, trochanteric bursitis, muscle tear or joint effusion.

Several patients were referred with hip pain following hip joint replacements. Post operative collections or muscle tears were suspected.

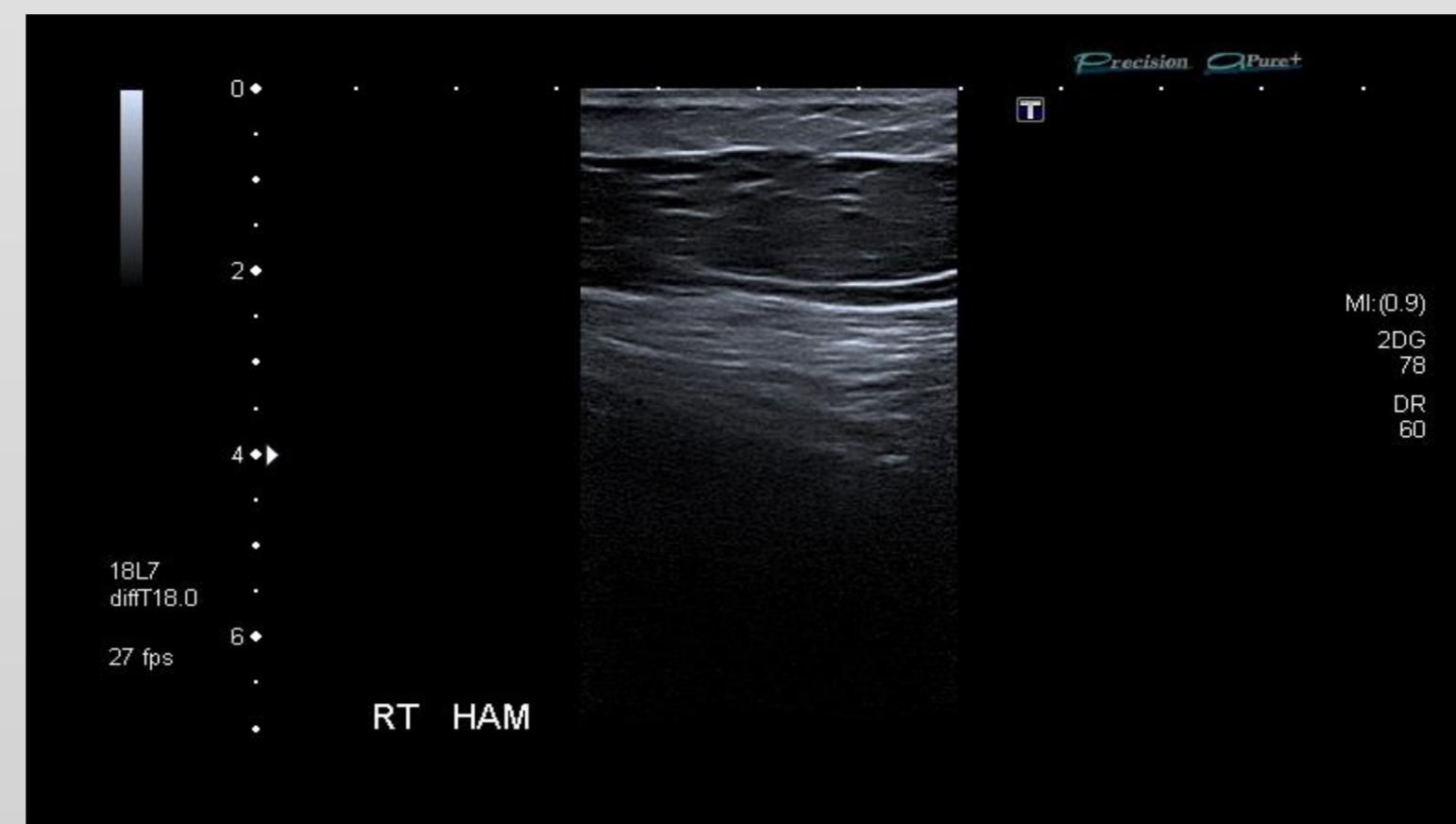


Fig.1: Normal Hamstring Tendon

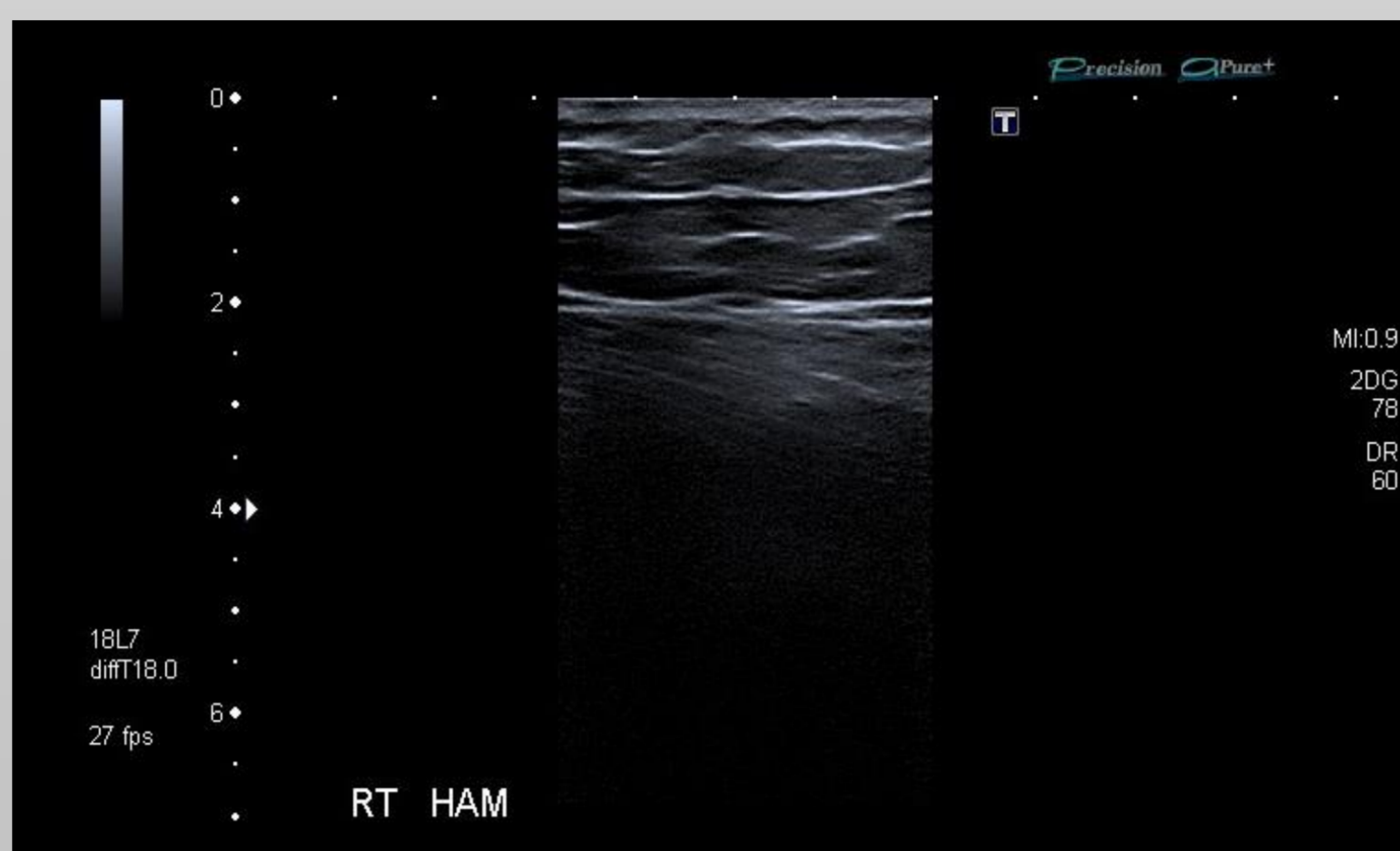


Fig.2: Normal Hamstring Tendon

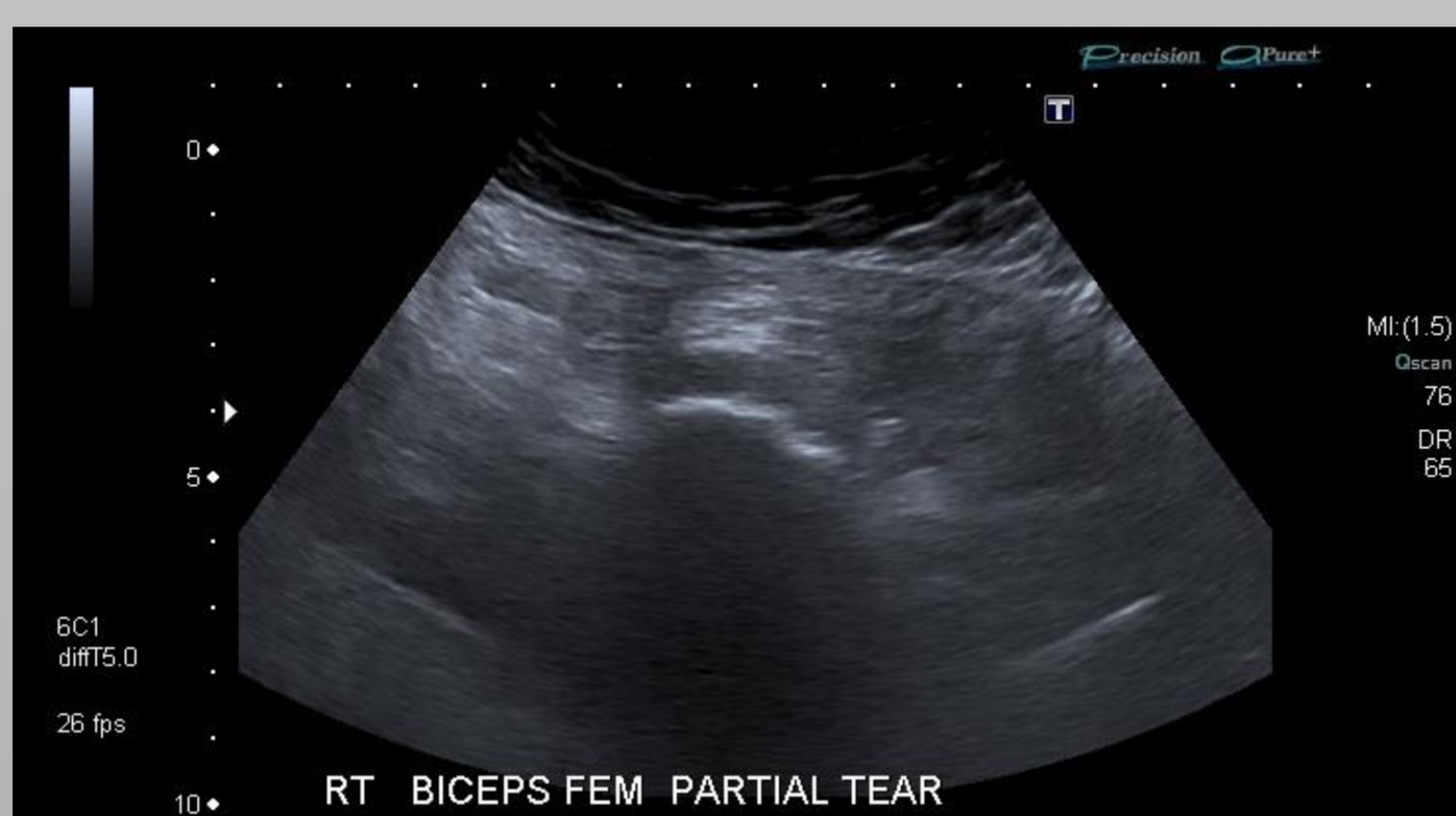


Fig.3A: Partial Biceps Femoris Tendon Tear – Transverse

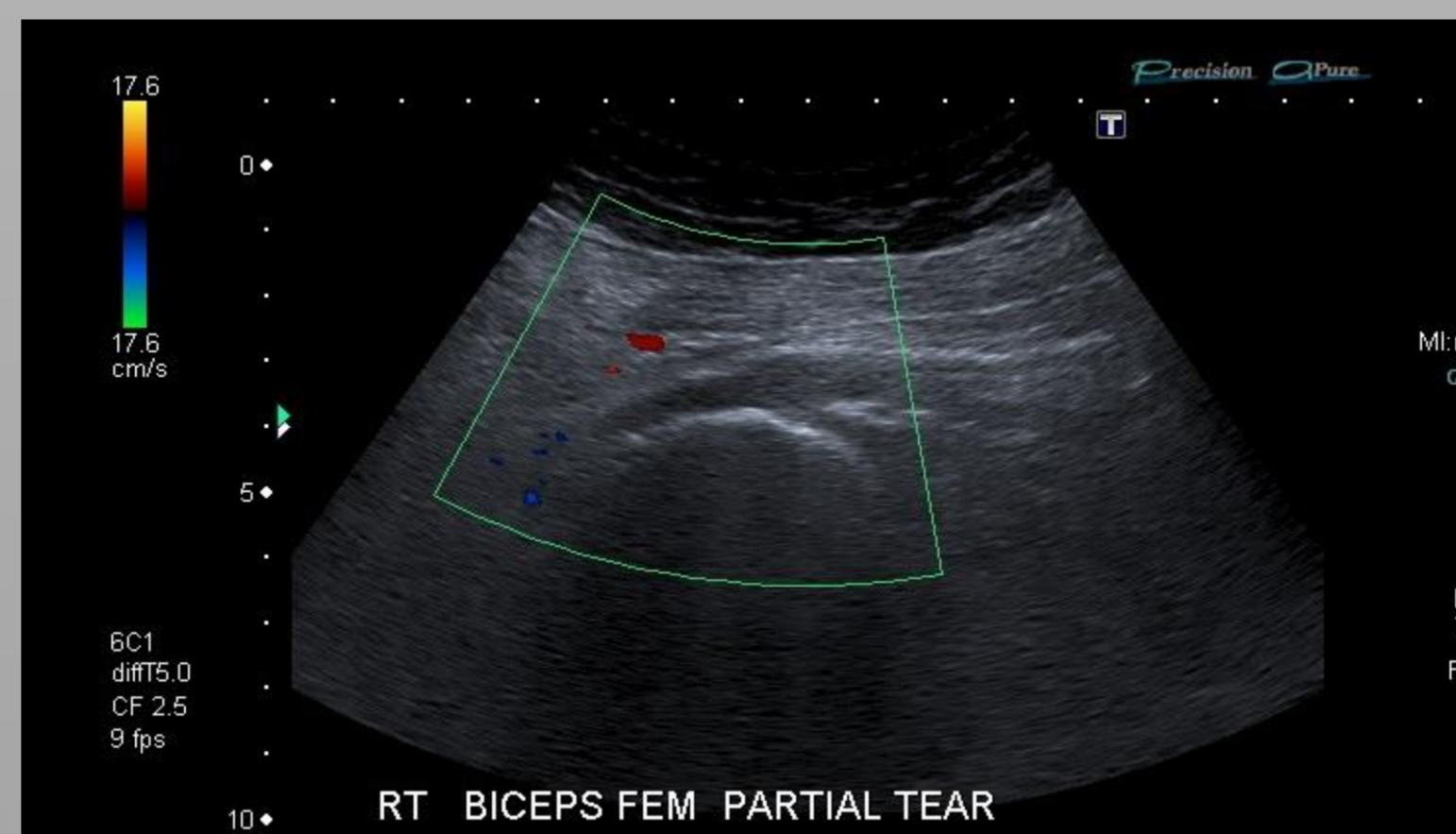


Fig. 3B: Partial Biceps Femoris Tendon Tear – Longitudinal

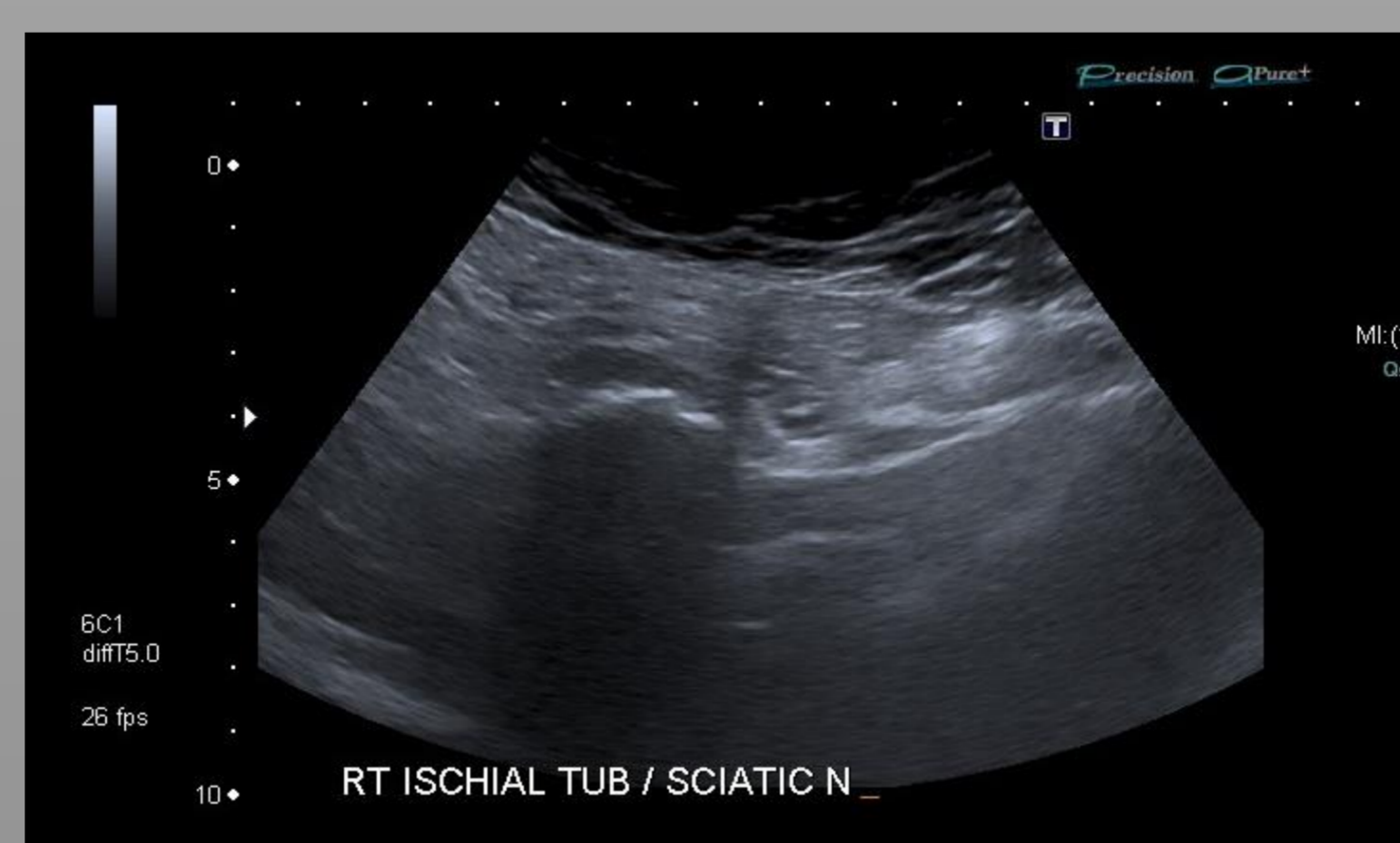


Fig.4: Partial Hamstring Tear – Transverse

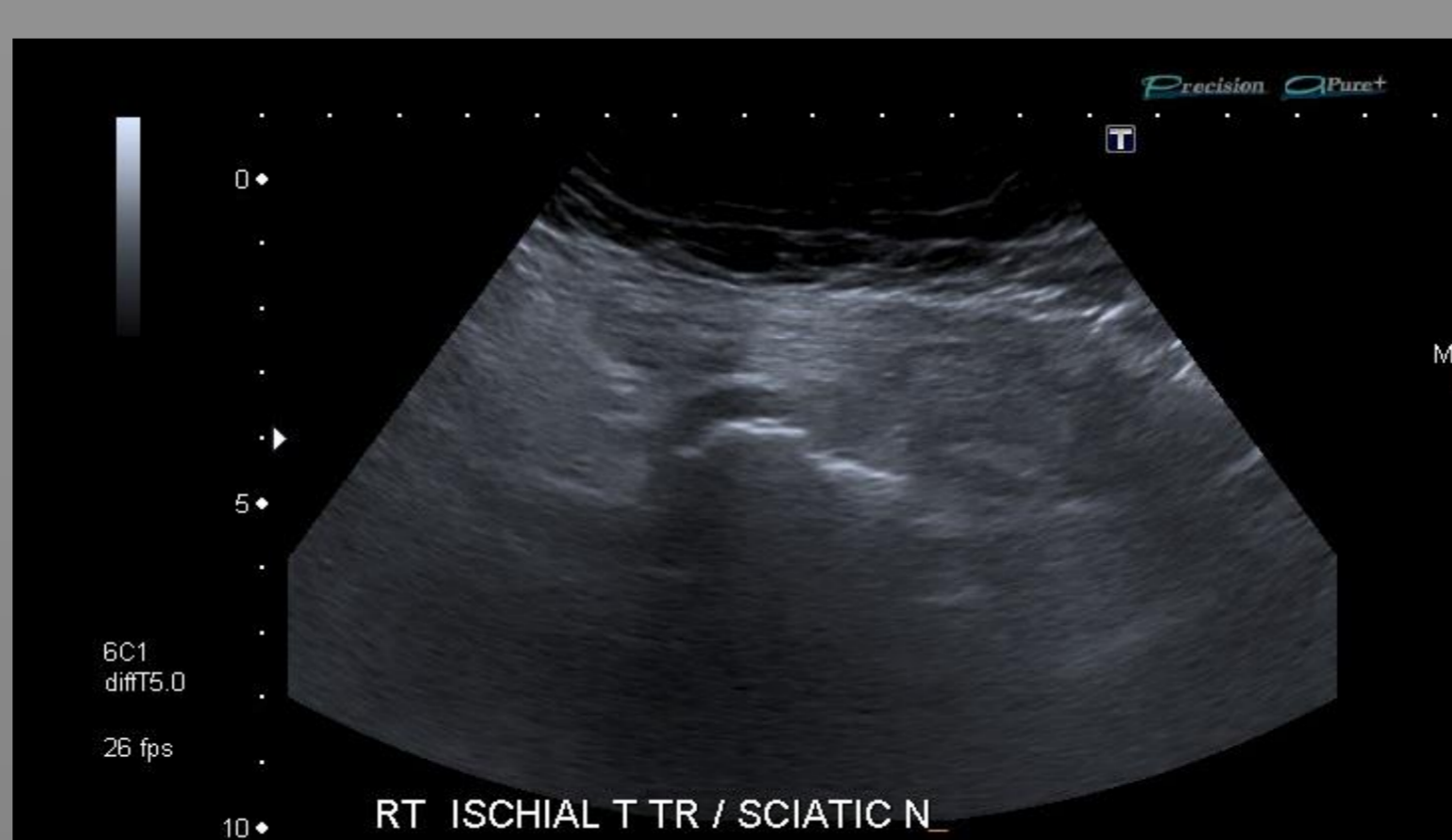


Fig. 5: Partial Hamstring Tear – Transverse

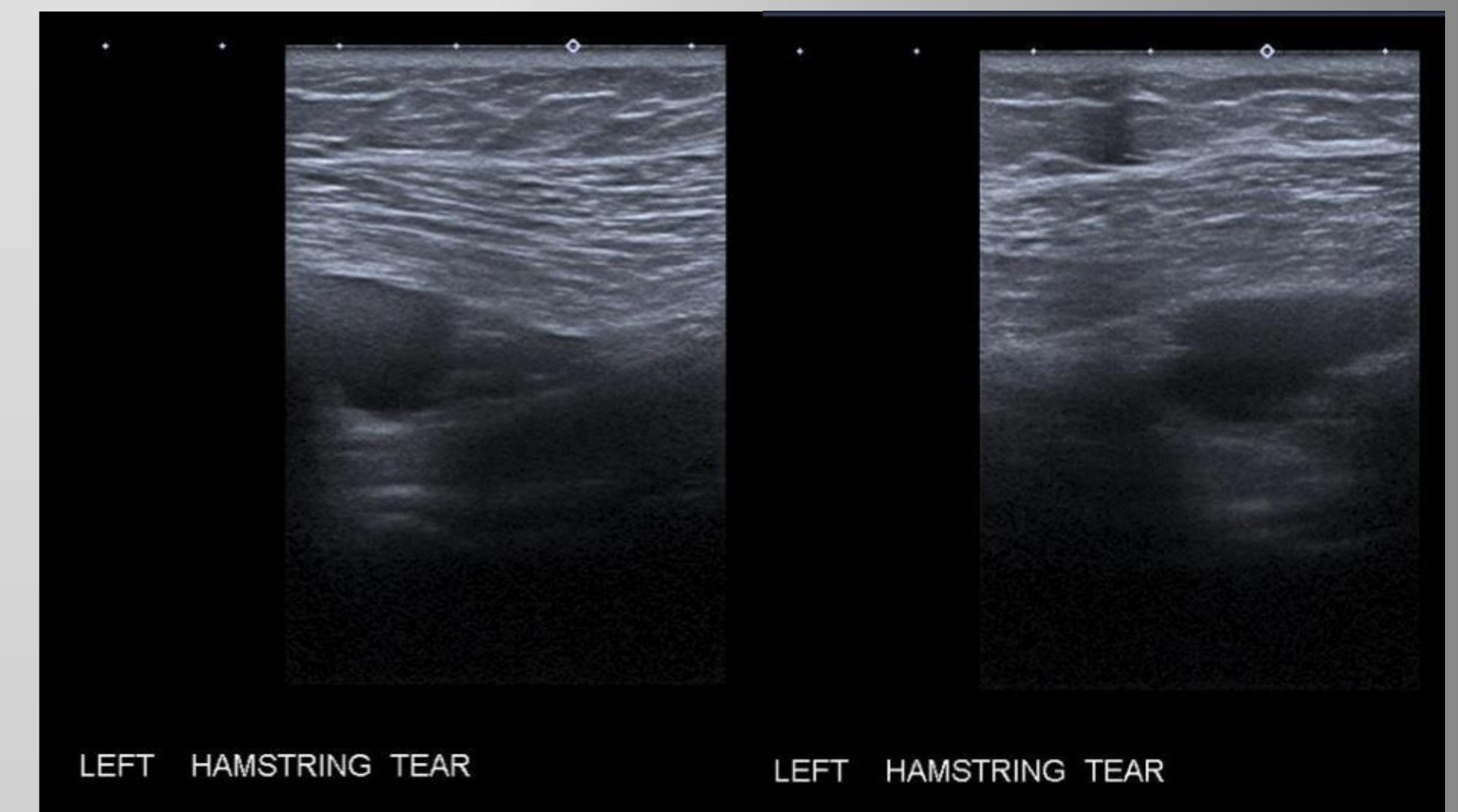


Fig. 6: Full thickness Hamstring Tear (Fluid filling the tendon tear gap)

Results:

35 patients had **unsuspected** hamstring tears.

2 patients were found to have **full thickness** hamstring tears. Both patients presented following falls after hip replacement surgery.

33 patients presented with unsuspected deep surface **partial hamstring tears** . Of these 33 patients, **7** had **bilateral partial** hamstring tears.

Conclusion:

Both full and partial thickness tears can be accurately diagnosed with **high resolution** ultrasound.

Ultrasound evaluation is particularly helpful in the post-operative setting (no artefact as compared to MRI), can be less time-consuming, as well as guide intervention.

Study Limitations:

- Small Cohort Size
- High BMI Patients

References:

- 1) Imaging of Hip Pain: *Radiography to Cross-Sectional Imaging Techniques*, September 2012.
- 2) Imaging Diagnosis and Prognostication of Hamstring Injuries - David A. Rubin. *American Journal of Roentgenology*. 2012;199: 525-533.
- 3) Hamstring Strain Injuries: Recommendations for Diagnosis, Rehabilitation and Injury Prevention. *Radiographics*. 2005 May-Jun;25(3):571-86.
- 4) Hamstring muscle complex: an imaging review. Koulouris G, Connell D.
- 5) Imaging of hamstring injuries: therapeutic implications. Koulouris G, Connell D.