

SCROTAL ULTRASOUND; IT'S NOT ALL ABOUT THE TESTES! PICTORIAL REVIEW OF COMMON (AND SOME UNCOMMON) EXTRA TESTICULAR ULTRASOUND FINDINGS

Justin Davies, Sonographer, Great Western Hospitals NHS Foundation Trust
Dr Nick Ridley, Consultant Radiologist, Great Western Hospitals NHS Foundation Trust

INTRODUCTION AND AIM

ULTRASOUND IS USED AS THE PRIMARY IMAGING MODALITY TO ASSESS THE SCROTUM FOR BOTH ACUTE AND CHRONIC CONDITIONS.

NICE (2022) RECOMMEND THAT PATIENTS BE REFERRED FOR ULTRASOUND OF THE SCROTUM WHERE THERE ARE UNEXPLAINED TESTICULAR SYMPTOMS OR SCROTAL SWELLING WHICH CANNOT BE DETERMINED WHETHER IT IS INTRA OR EXTRA TESTICULAR; THIS IS OFTEN WHEN A PATIENT HAS INCIDENTALLY FOUND SOMETHING ABNORMAL WHILST EXAMINING THEMSELVES OR HAVE EXPERIENCED SCROTAL PAIN. THESE SYMPTOMS CAN OFTEN BE EXTRA-TESTICULAR IN ORIGIN.

A VARIETY OF APPROPRIATE EXTRA-TESTICULAR SCROTAL ULTRASOUND CASES WERE IDENTIFIED AND ASSESSED AND ALL CASES WERE SEEN DURING 2021 TO 2022 AT THE GREAT WESTERN HOSPITAL, SWINDON.

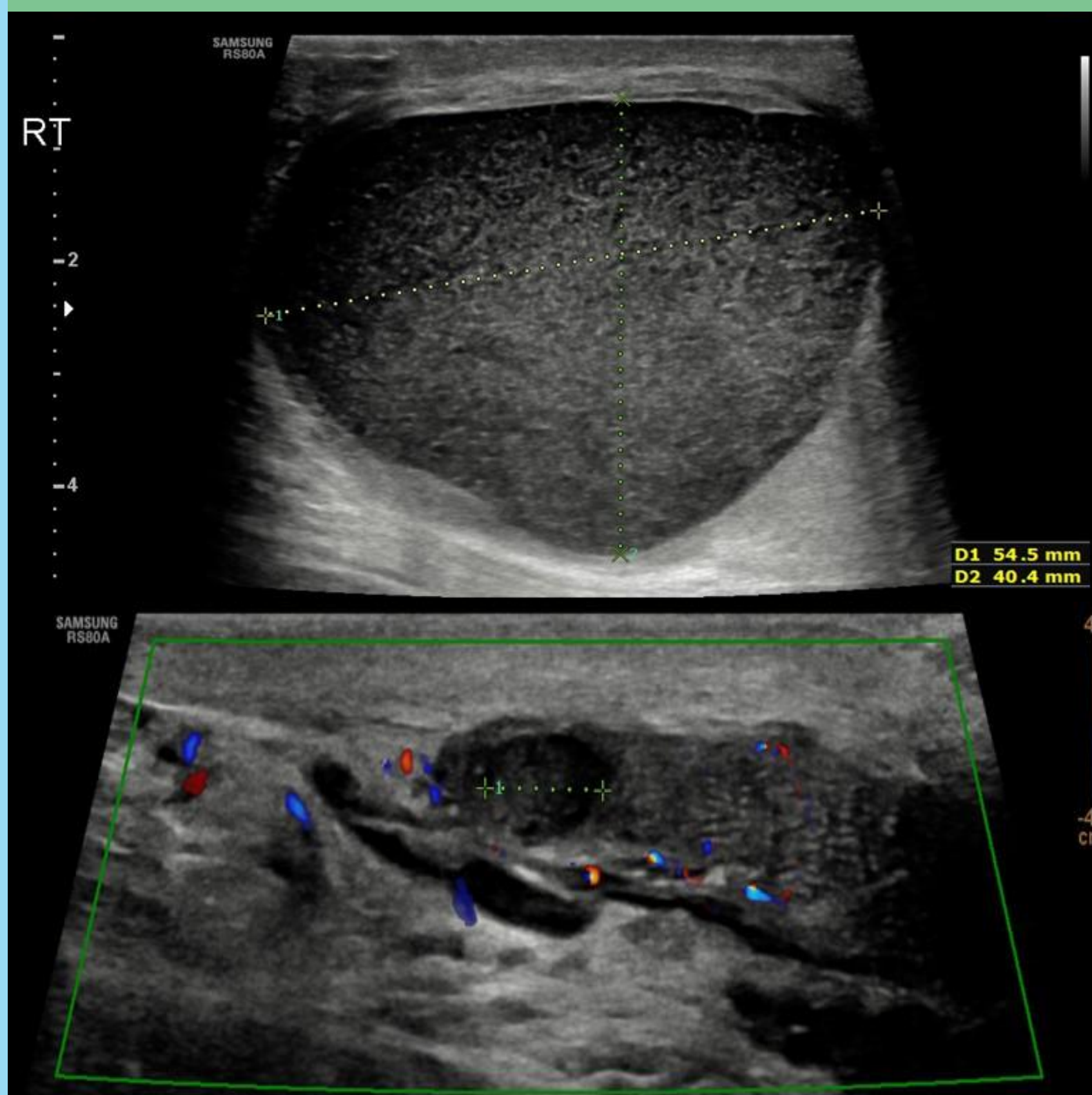
THIS POSTER AIMS TO DEMONSTRATE A WIDE RANGE OF EXTRA-TESTICULAR SCROTAL PATHOLOGY AND TO BE VIEWED AS AN EDUCATIONAL GUIDE FOR SONOGRAPHERS, HEALTH PROFESSIONALS AND CLINICIANS WITH AN INTEREST IN SCROTAL ULTRASOUND, SHOWING THE COMMON AND SOME UNCOMMON EXTRA-TESTICULAR FINDINGS THAT MAY BE FOUND.

EPIDIDYMAL LESIONS

PATIENTS IN THESE CASES PRESENTED WITH ROUND LUMPS AT THE UPPER OR LOWER POLES OF THE TESTES

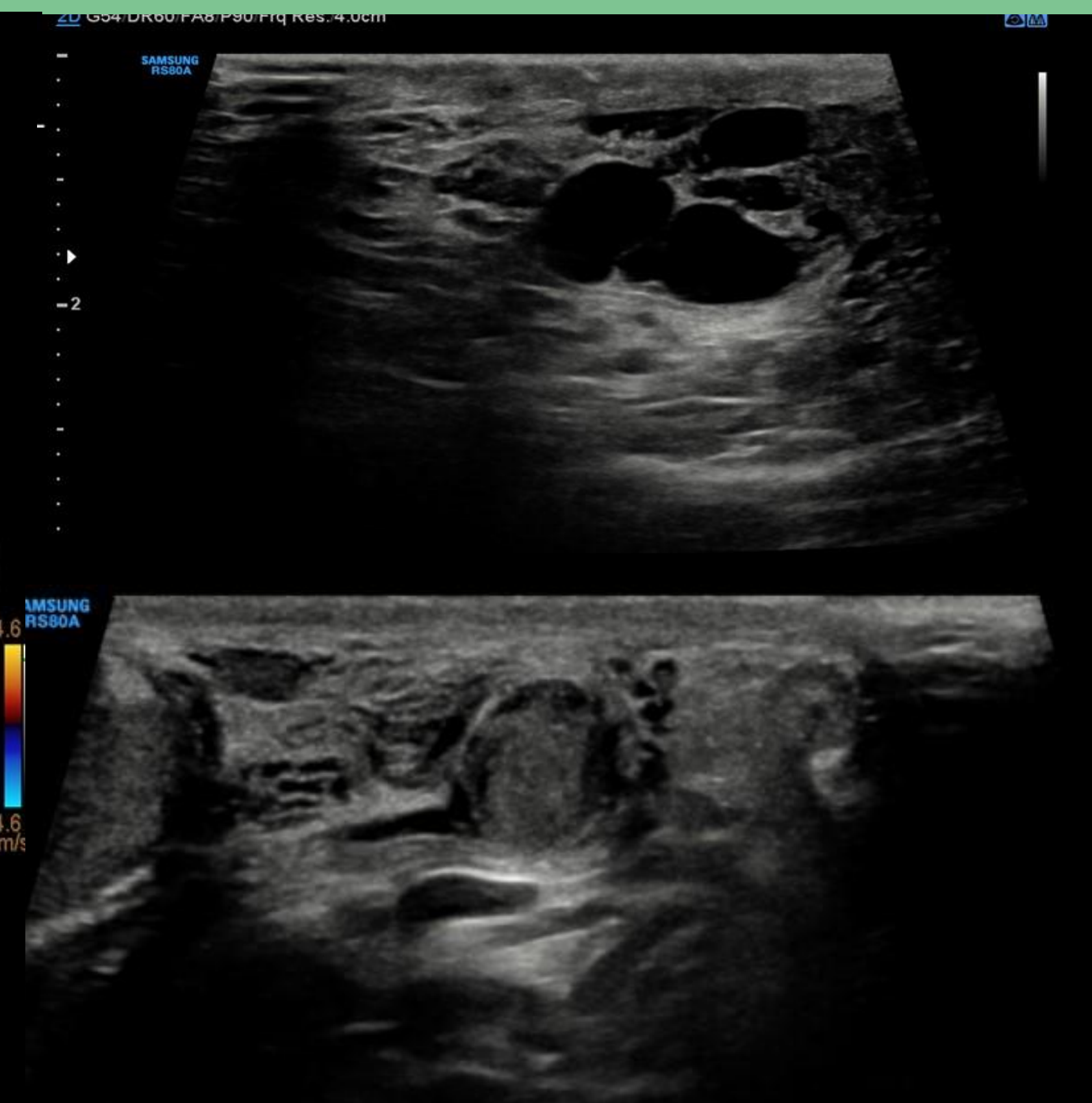
SPERMATOCELE

THIN WALLED CYST WITH LOW LEVEL ECHOES WITHIN



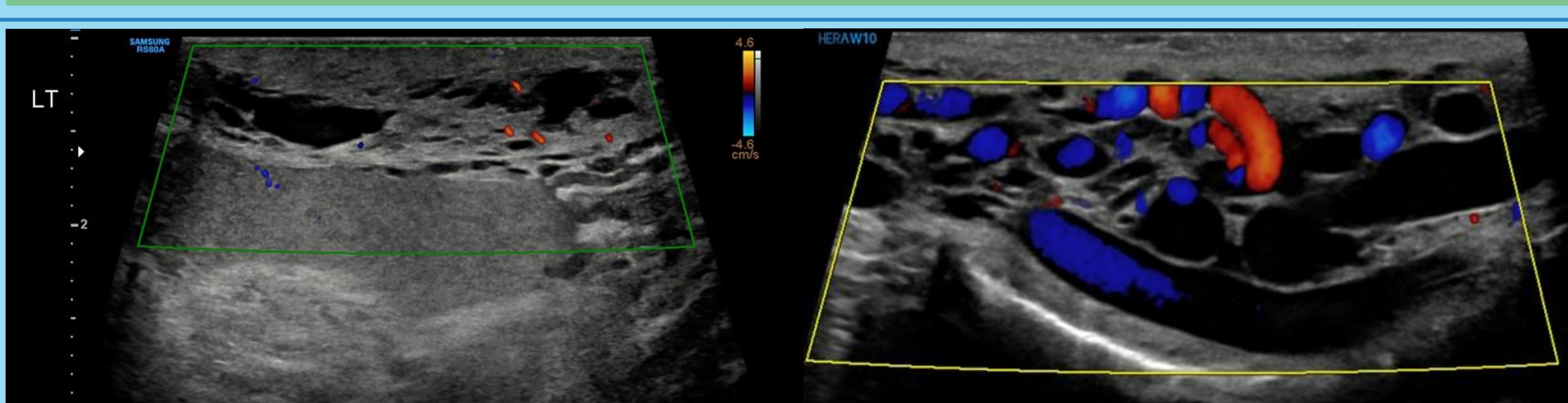
SIMPLE EPIDIDYMAL CYSTS

THIN WALLED ANECHOIC CYSTS



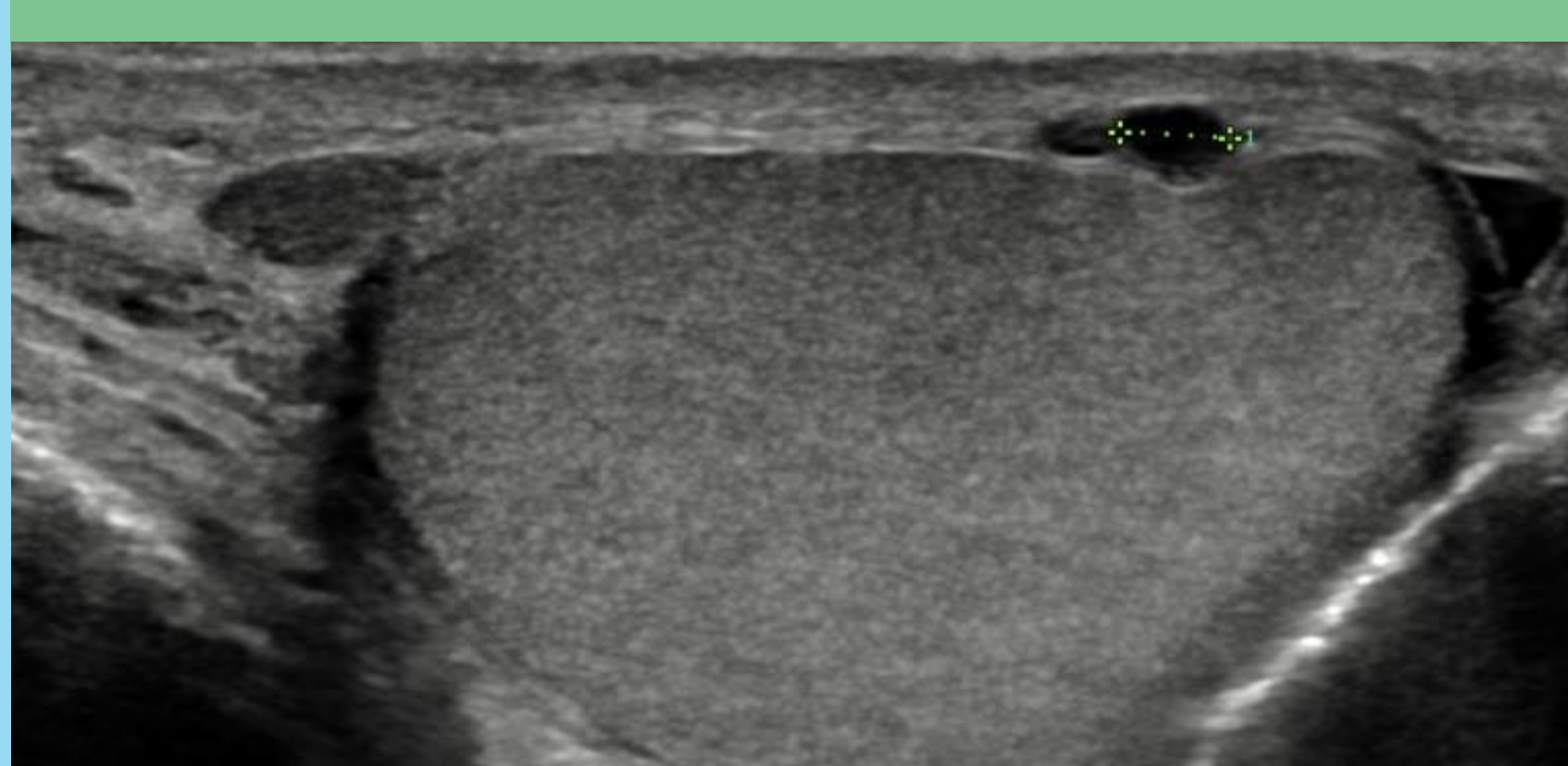
SPERM GRANULOMAS

HETEROGENOUS ROUND AND WELL DEFINED LESIONS WITH NO INTERNAL VASCULARITY, CAN CONTAIN CALCIFICATION, OFTEN BE ASSOCIATED WITH PREVIOUS VASECTOMY



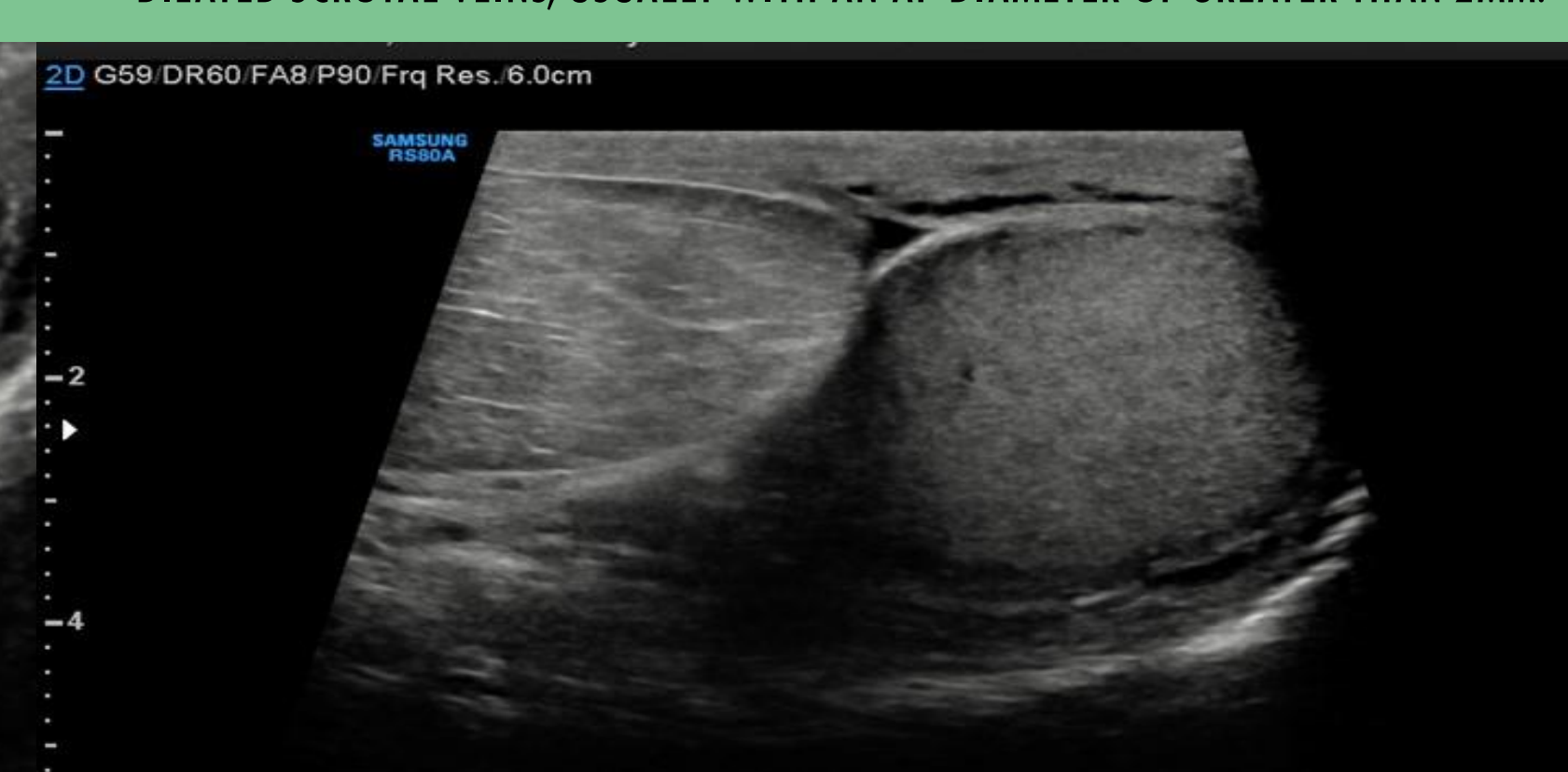SCROTAL WALL THICKENING

PATIENT PRESENTED AFTER PREVIOUS SURGERY FOR CYST REMOVAL AND FURTHER EXPLORATORY SURGERY. THICKENED CYSTIC SCROTAL WALL



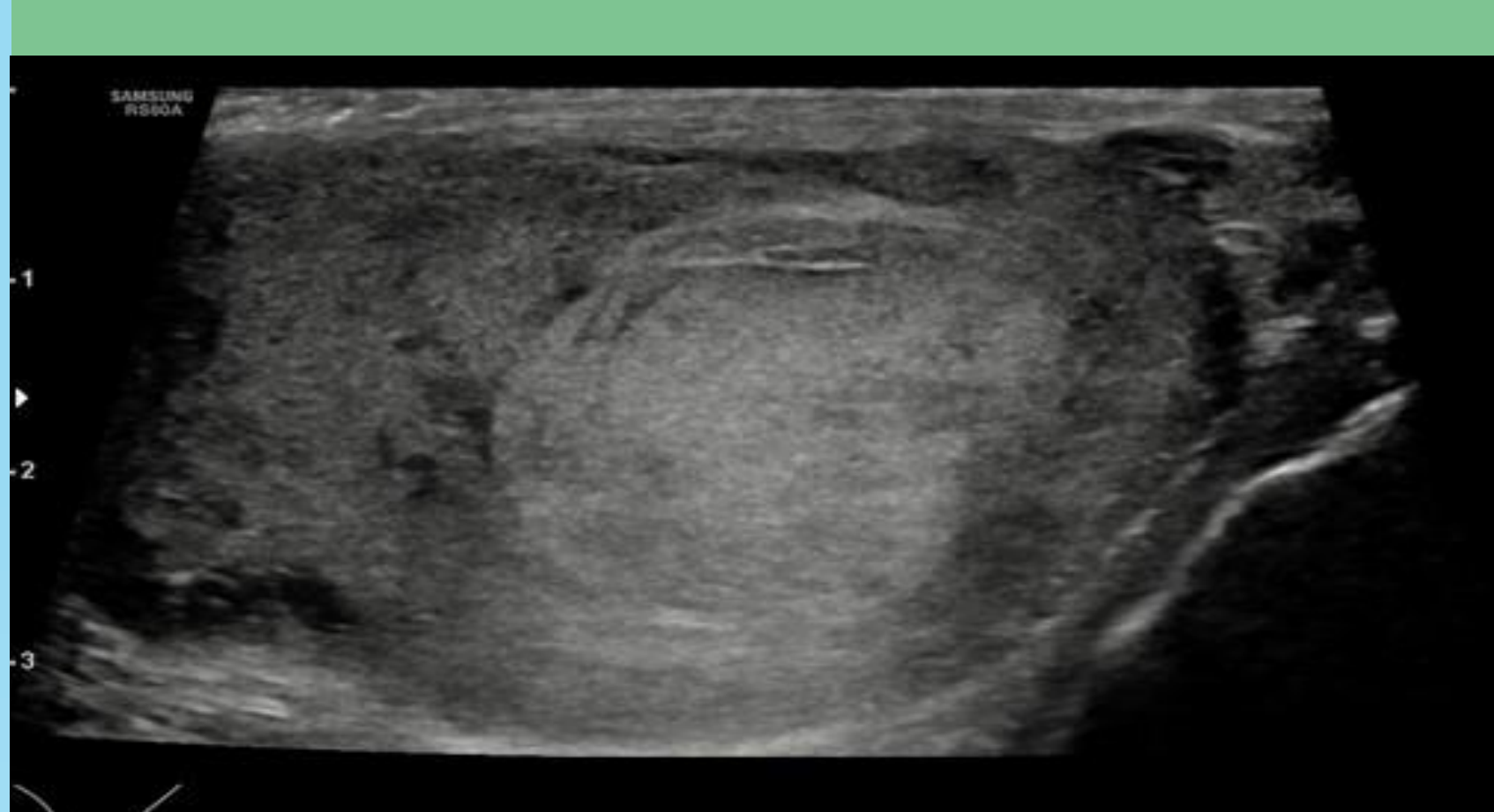
VARICOCELE

PATIENT PRESENTED WITH DULL ACHE IN THE SCROTUM AND A LUMPY FEELING. DILATED SCROTAL VEINS, USUALLY WITH AN AP DIAMETER OF GREATER THAN 2MM.



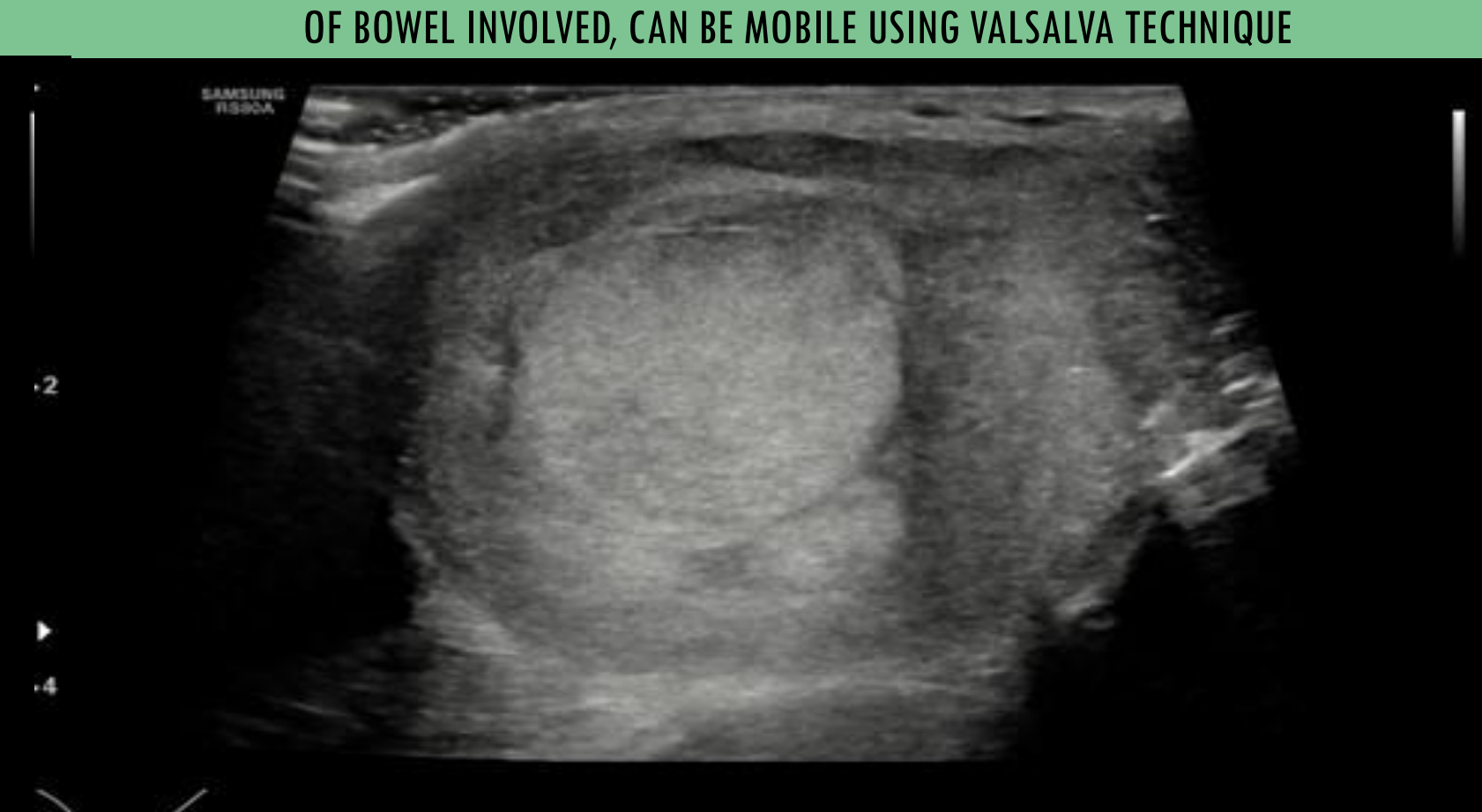TUNICA ALBUGINEA CYSTS

CYSTS ARISING FROM THE TUNICA ALBUGINEA COMMONLY WELL ROUNDED THIN WALLED AND SIMPLE IN APPEARANCE.



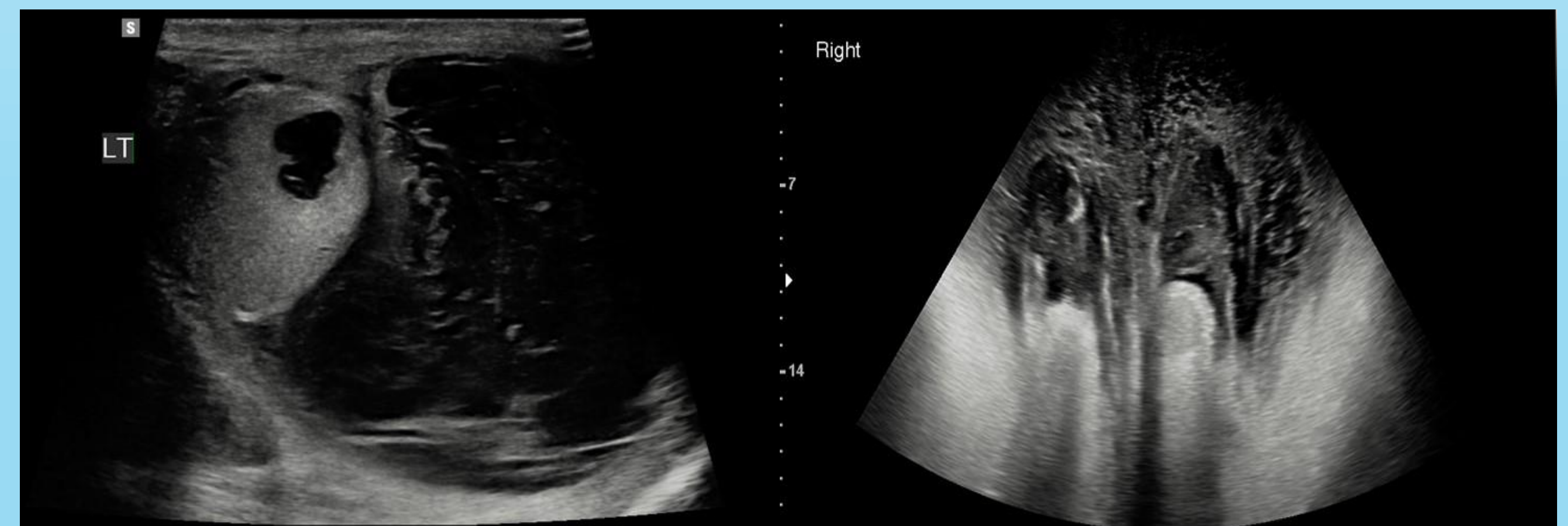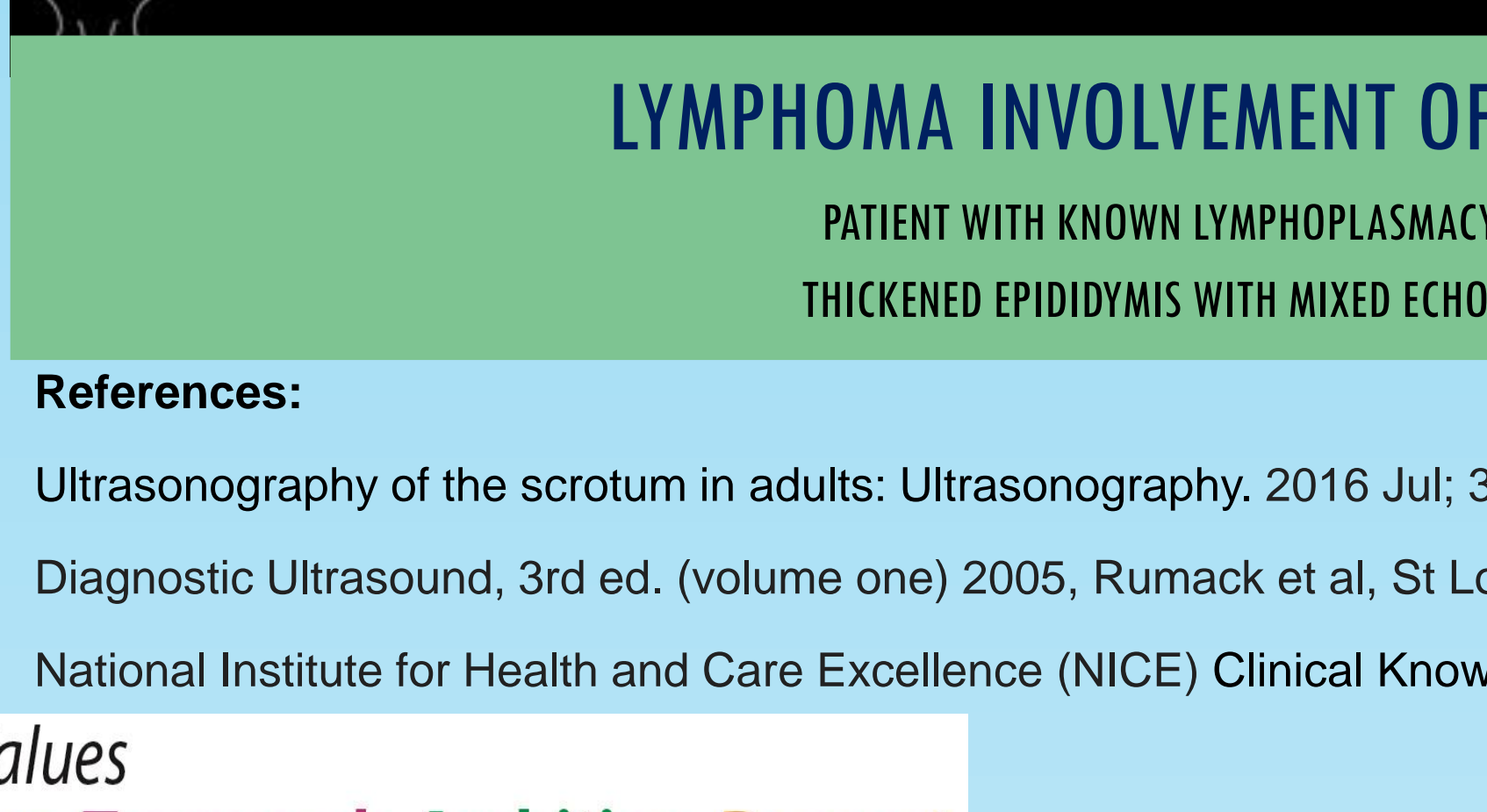
SCROTAL HERNIA

PATIENT PRESENTED WITH TENSE GROIN AND SWELLING WITHIN THE SCROTUM.. INGUINOSCROTAL HERNIAS CAN HAVE A HYPERECHOIC APPEARANCES WHEN CONTAINING FAT (AS ABOVE) OR A MORE MIXED ECHOGENIC APPEARANCE IF THERE IS SIGNIFICANT AMOUNT OF BOWEL INVOLVED, CAN BE MOBILE USING VALSALVA TECHNIQUE



LYMPHOMA INVOLVEMENT OF THE EPIDIDYMIS AND TESTICLE

PATIENT WITH KNOWN LYMPHOPLASMACYTIC LYMPHOMA, NEW TESTICULAR SWELLING. THICKENED EPIDIDYMIS WITH MIXED ECHOGENIC APPEARANCE AND INDISTINCT MARGINS

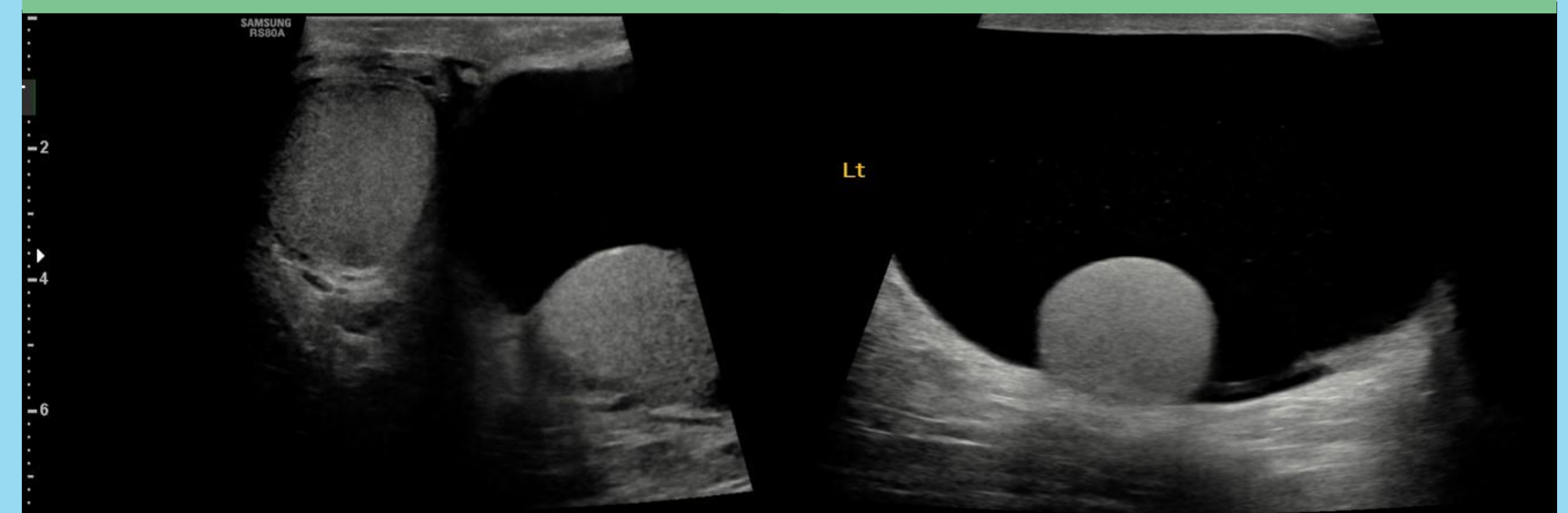


SCROTAL HAEMATOCELE WITH ASSOCIATED TESTICULAR TRAUMA

THE PATIENT PRESENTED AFTER BEING KICKED IN THE GROIN DURING A SPORTS GAME. FLUID SURROUNDING THE TESTIS WITH AN INCREASED/MIXED ECHOGENIC APPEARANCE, CAN HAVE SEPTATIONS WITHIN.

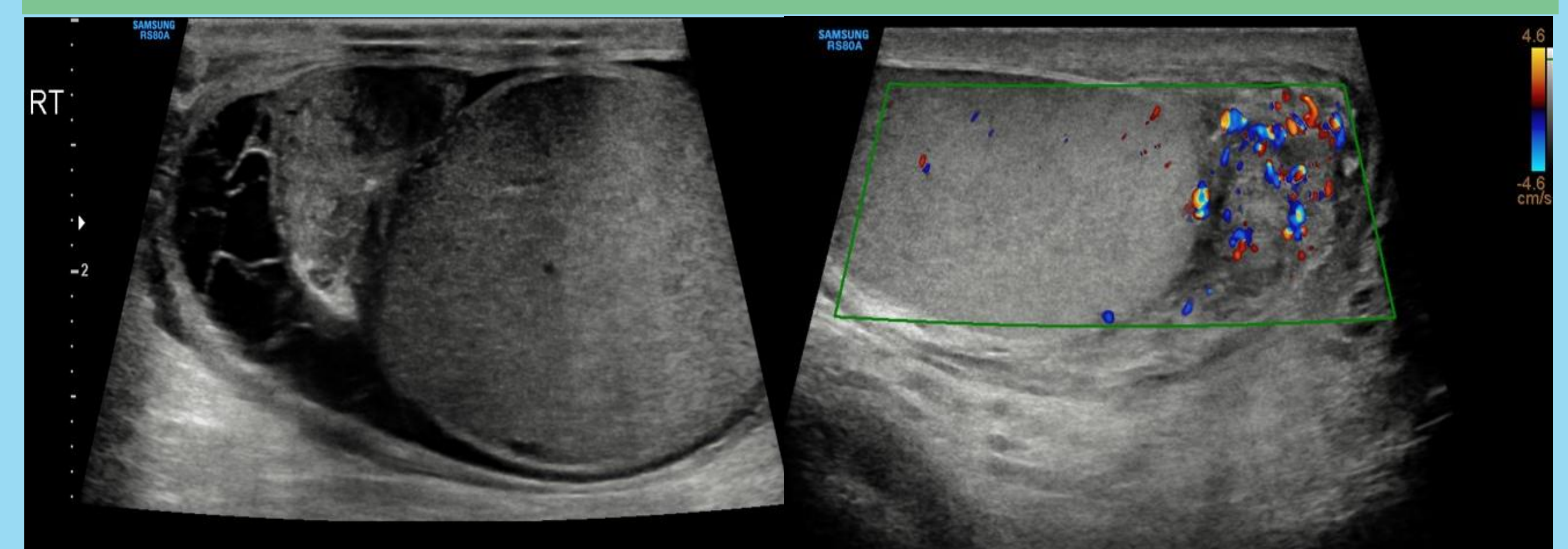
SCROTAL OEDEMA

PATIENT PRESENTED WITH SCROTAL SWELLING, BMI OF 65 AND KNOWN LOWER LIMB LYMPHOEDEMA . THICKENED OEDEMATOUS SCROTAL WALL OFTEN WITH INCREASED VASCULARITY USING COLOUR DOPPLER.



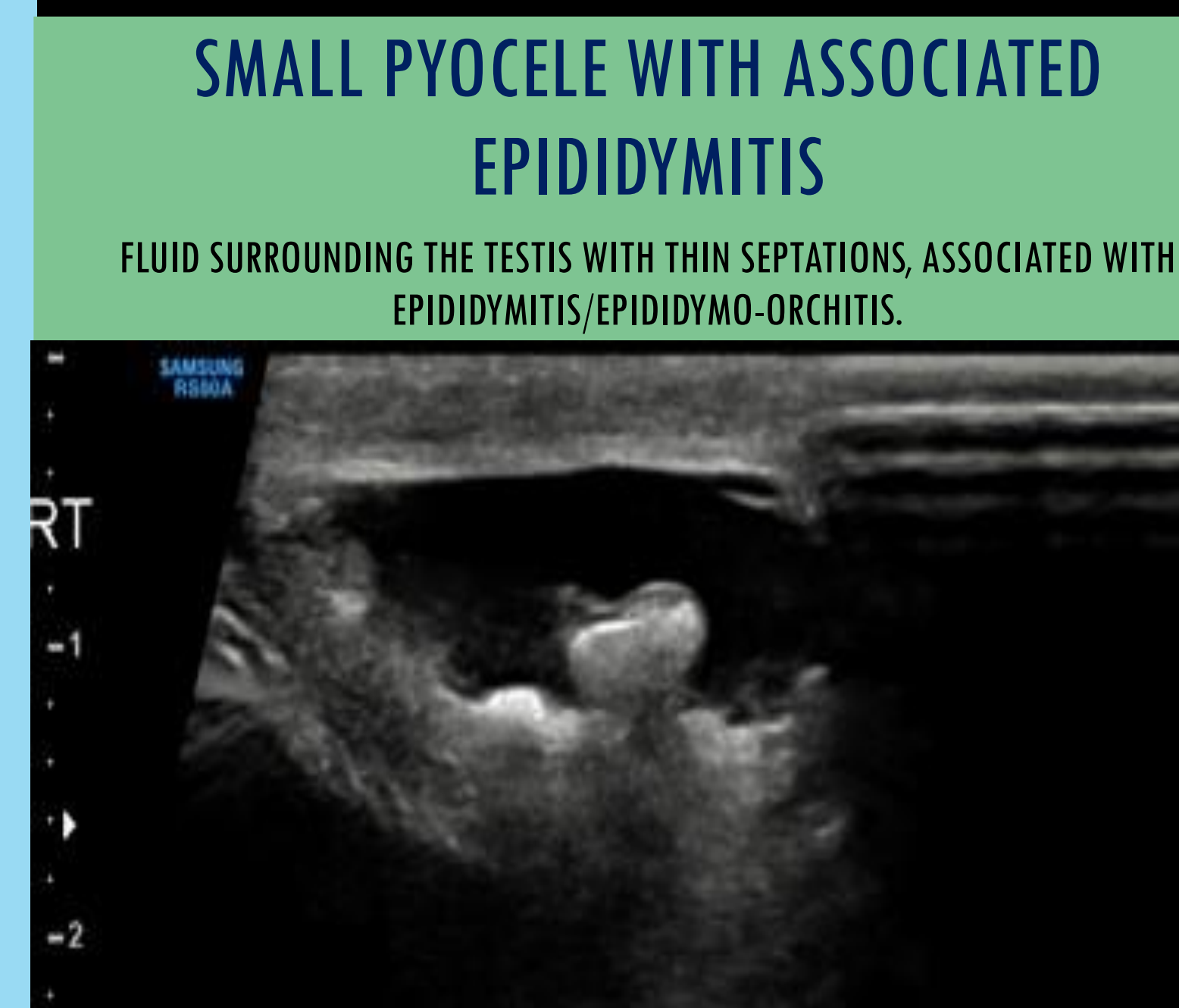
HYDROCELES

FLUID SURROUNDING THE TESTIS, GENERALLY ANECHOIC AND CAN BE DIAGNOSED VIA TRANSLUMINATION PATIENTS PRESENT WITH SCROTAL SWELLING



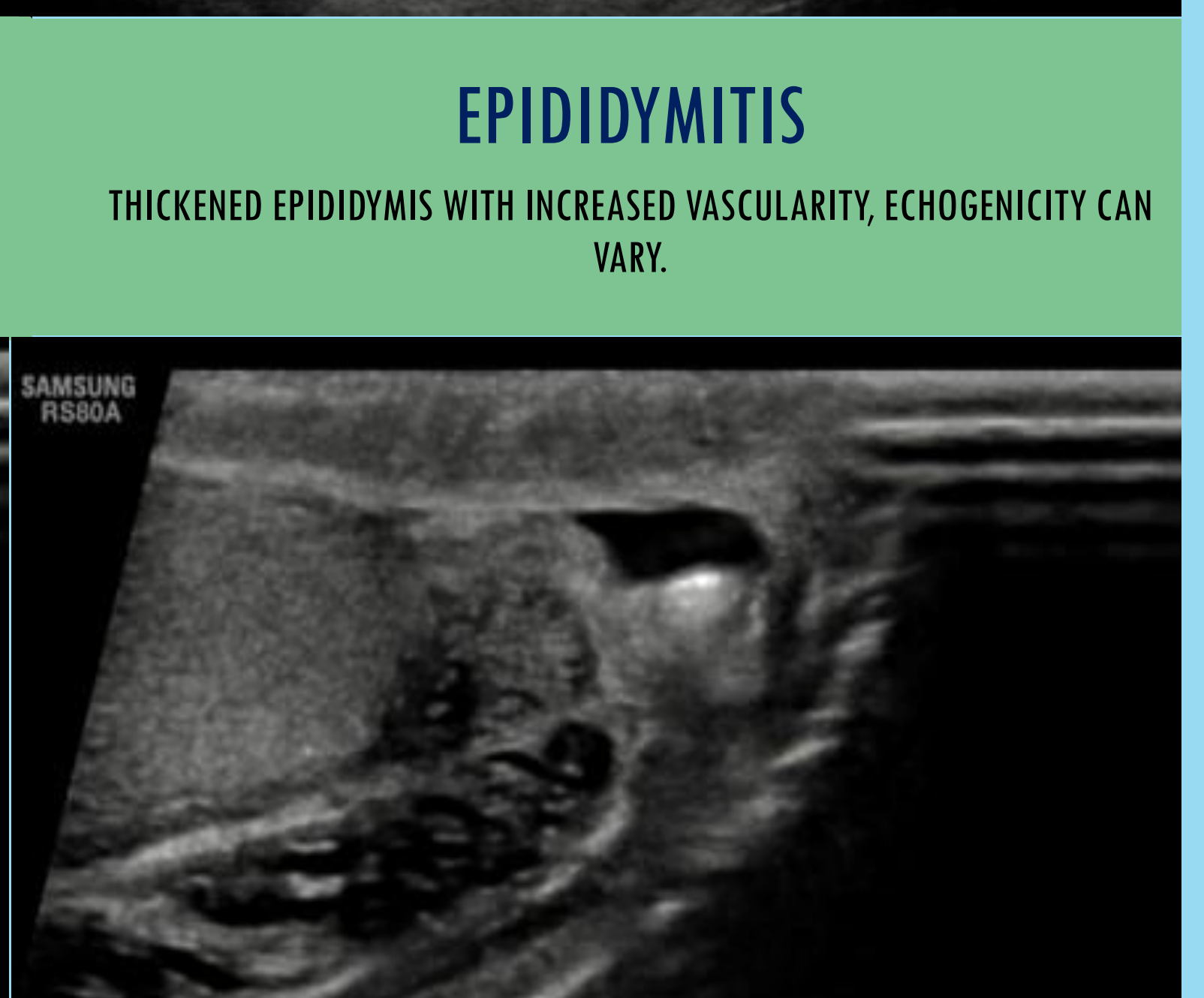
SMALL PYOCELE WITH ASSOCIATED EPIDIDYMITIS

FLUID SURROUNDING THE TESTIS WITH THIN SEPTATIONS, ASSOCIATED WITH EPIDIDYMITIS/EPIDIDYMO-ORCHITIS.



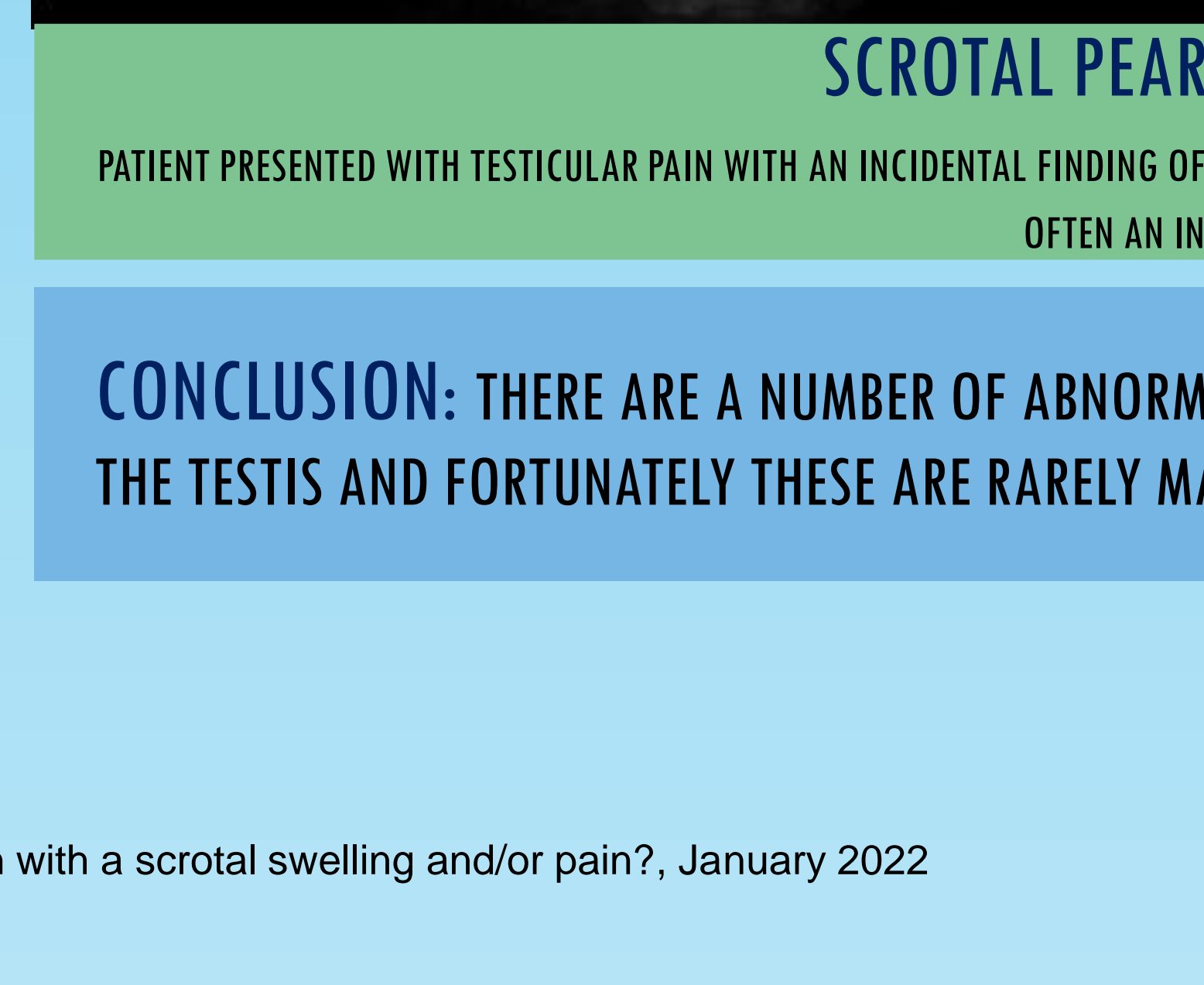
EPIDIDYMITIS

THICKENED EPIDIDYMIS WITH INCREASED VASCULARITY, ECHOGENICITY CAN VARY.



SCROTAL PEARLS / SCROTOLITHS

PATIENT PRESENTED WITH TESTICULAR PAIN WITH AN INCIDENTAL FINDING OF SCROTAL PEARLS. LOOSE CALCIFIED BODIES, CAN SOMETIME BE FELT BY THE PATIENT, OFTEN AN INCIDENTAL FINDING.



CONCLUSION: THERE ARE A NUMBER OF ABNORMALITIES THAT CAN BE FOUND IN THE SCROTUM OUTSIDE THE TESTIS AND FORTUNATELY THESE ARE RARELY MALIGNANT.

References:

- Ultrasonography of the scrotum in adults: Ultrasonography. 2016 Jul; 35(3): 180-197.2016 Feb 24. Kuhn et al
- Diagnostic Ultrasound, 3rd ed. (volume one) 2005, Rumack et al, St Louis, Elsevier Mosby.
- National Institute for Health and Care Excellence (NICE) Clinical Knowledge Summaries Scrotal pain and swelling: How should I assess a person with a scrotal swelling and/or pain?. January 2022