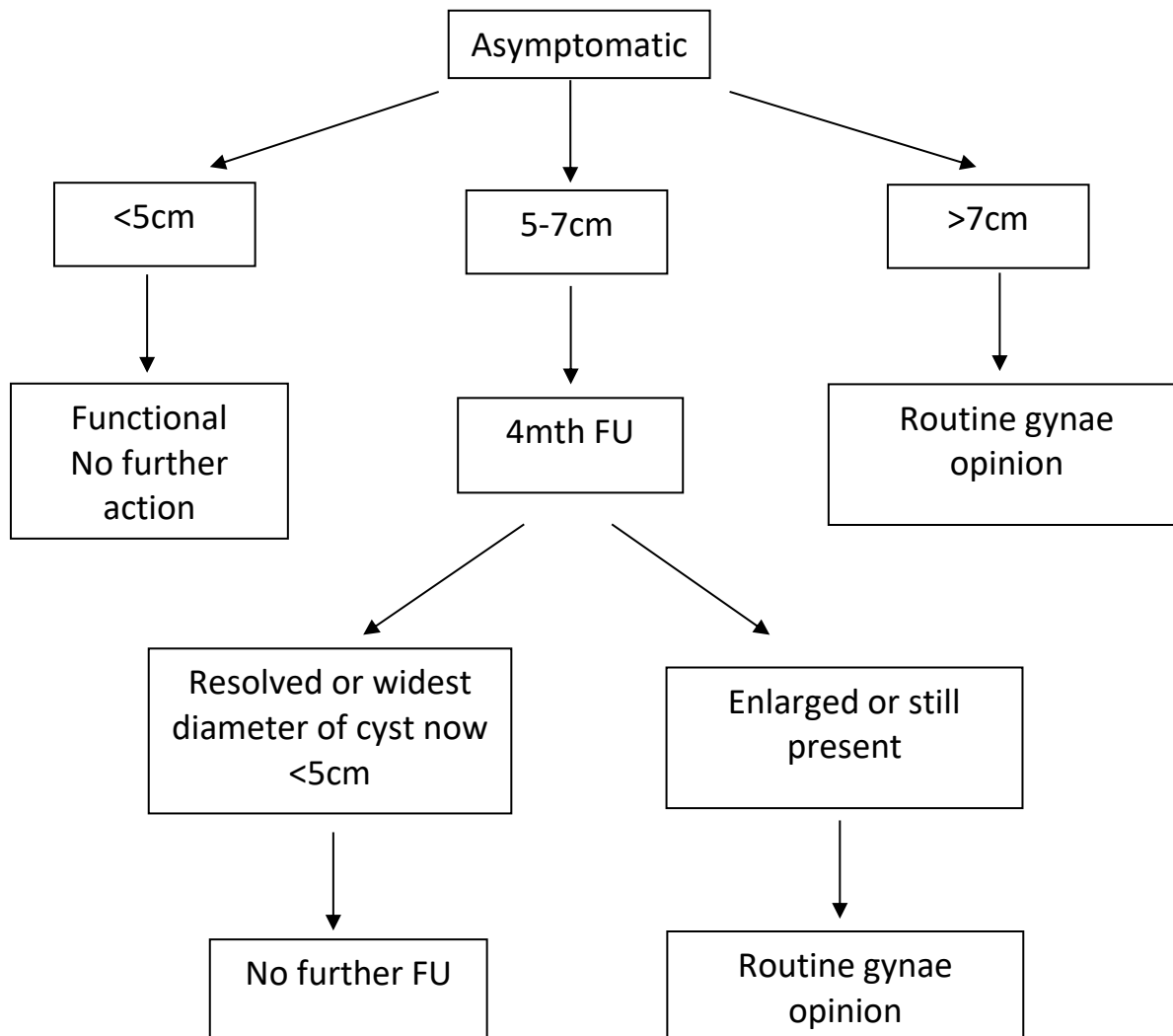


## Simple pre-menopausal ovarian cysts

**A simple cyst is a round or oval anechoic space with smooth thin walls, posterior acoustic enhancement, no solid component or septation and no internal flow at color Doppler ultrasound.**

**Transabdominal and transvaginal scans are recommended.**



- The following cysts should also be treated as simple and the same size thresholds used :para ovarian cysts where the ovary can be seen separately, cysts containing daughter cysts and cysts with one thin septation (<3mm) or small calcification in wall.
- Always refer to previous imaging if available CT/MRI/US.
- Make explicit in the report who is to arrange follow up.
- Symptomatic cysts may need referral.
- If there is any increasing complexity or pointers to malignancy at ultrasound, 2ww gynaecological referral is recommended.

### References

- Levine D et al. Management of Asymptomatic Ovarian and other Adnexal Cysts Imaged at US: Society of Radiologist in Ultrasound Consensus Conference Statement. *Radiology* 2010;256:943-954
- Levine D et al. Simple Adnexal Cysts: SRU Consensus Conference Update on Follow-up and Reporting. *Radiology* 2019;203:2, 359-371.

