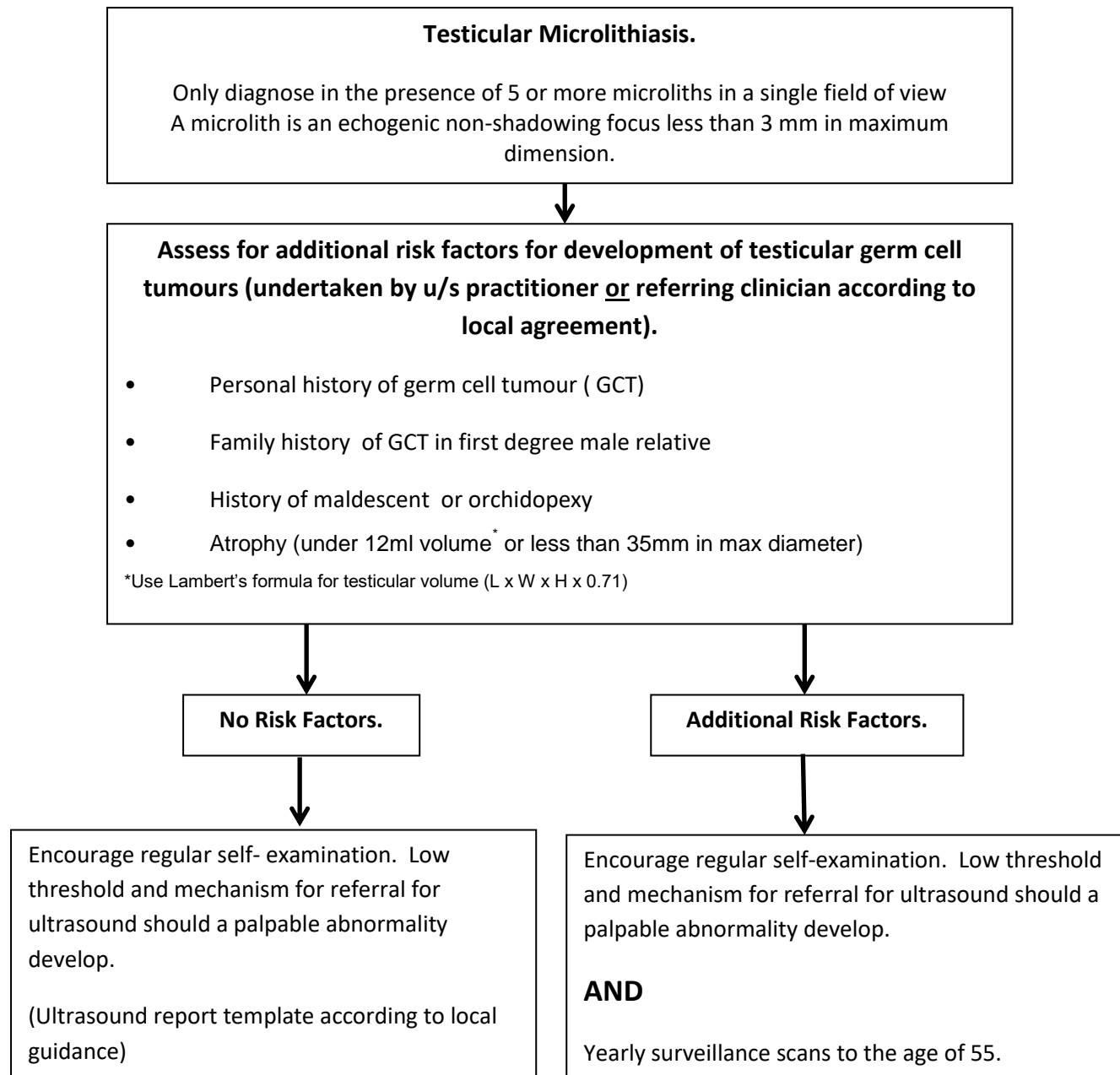


Ultrasound Management of Testicular Microlithiasis.

- Testicular microlithiasis is a common finding on scrotal ultrasound.
- While there has been concern that this may be a risk factor for development of a subsequent testicular germ cell tumour, its significance remains controversial.
- This algorithm aims to standardise management where testicular microlithiasis has been discovered on scrotal ultrasound.



References

- Gorman and Carroll. The scrotum. In: Rumack C, Wilson S, Charboneau J (eds). Diagnostic Ultrasound. Vol. 1. Philadelphia. Mosby; 2005 866-867.
- Lam D, Gersovich E et al. Testicular Microlithiasis. Our experience of 10 years. J Ultrasound Med 2007; 26:867-873
- Miller F, Rosairo S et al. Testicular calcification and microlithiasis: Association with primary intra-testicular malignancy in 3,477 patients. Eur Radiol 2007; 17:363-369.
- Backus M, Mack L et al. Testicular microlithiasis: imaging appearances and pathologic correlation. Radiology.
- DeCastro B, Peterson A. A 5 year followup study of asymptomatic men with testicular microlithiasis. J. Urology 2008; 179(4):1420-1423
- Richiardi L, Pettersson A et al. Genetic and environmental risk factors for testicular cancer. International Journal of Andrology 2007; 30:230-241
- Leblanc L et al. Testicular microlithiasis and testicular tumor: a review of the literature. Basic Clin Androl. 2018; 28:8.
- Richenburg et al. Testicular microlithiasis imaging and follow-up: guidelines of the ESUR scrotal imaging subcommittee. Eur Radiol 2015; 25:323-330
- Hsieh ML, Huang ST, Huang HC, Chen Y, Hsu YC. The reliability of ultrasonographic measurements for testicular volume assessment: comparison of three common formulas with true testicular volume. Asian J Androl. 2009;11(2):261-265. doi:10.1038/aja.2008.48

Agreed by the Diagnostic Regional Ultrasound Group

Review date : October 2022